

# Pregnancy after embolization of an ovarian varicocele associated with infertility: report of two cases

Pavel Tarazov, Kirill Prozorovskij, Svetlana Rumiantseva

## ABSTRACT

We describe two cases of left-sided ovarian varicocele in patients with infertility. Pregnancy occurred in both women after successful retrograde venous embolization. Ovarian varicocele may be associated with infertility in some patients.

*Key words:* • veins • ovary • varicocele • infertility • therapeutic embolization • pregnancy

Ovarian varicocele is a well-known cause of pelvic pain in women (1–3). Surgical or laparoscopic ligation, or retrograde transcatheter embolization is successfully used for treatment of symptomatic cases (1–6).

In 1991, Galkin et al. (7) hypothesized that long-lasting ovarian varicocele might cause hypofunction of the ovaries and, similar to testicular varicocele, could be a cause of infertility. This hypothesis is not yet proven in the medical literature. We report two cases of pregnancy in women with infertility after successful transcatheter embolization of ovarian varices.

## Case reports

### Case 1

A 43-year-old woman presented with chronic pelvic pain of three years duration. Her pain increased after physical activity and during menses. She had given birth to a full-term baby 20 years prior to presentation. She has not become pregnant since that time, despite a lack of contraception during the last 7 years. Repeated gynecologic examinations including hysterosalpingography did not reveal any source of pelvic pain. No disorder of hormonal milieu was noted on endocrine evaluation.

Abdominal ultrasound did not reveal any gynecologic pathology such as leiomyoma, adenomyosis, or endometriosis, but it showed marked dilatation of veins around the left ovary. The diameter of the left ovarian vein trunk was 12 mm.

The presence of left ovarian varicocele was confirmed by selective retrograde venography. The right transjugular approach was used, because the patient had several large moles on both groins. A Headhunter 1 catheter (Cordis, Bridgewater, New Jersey, USA) was placed in the left renal vein, and then in the left ovarian vein. Embolization of the dilated left ovarian vein was performed with three long and four short homemade steel coils 10–12 mm in diameter (Fig. 1). The right ovarian vein was not dilated.

During the next month, the patient had significant reduction of pelvic pain, which eventually disappeared completely. Ultrasound (US) examination showed occlusion and fibrosis of the left ovarian vein, and disappearance of pelvic varices. Three months after the procedure, the patient became pregnant. The pregnancy was normal, and resulted in an easy delivery.

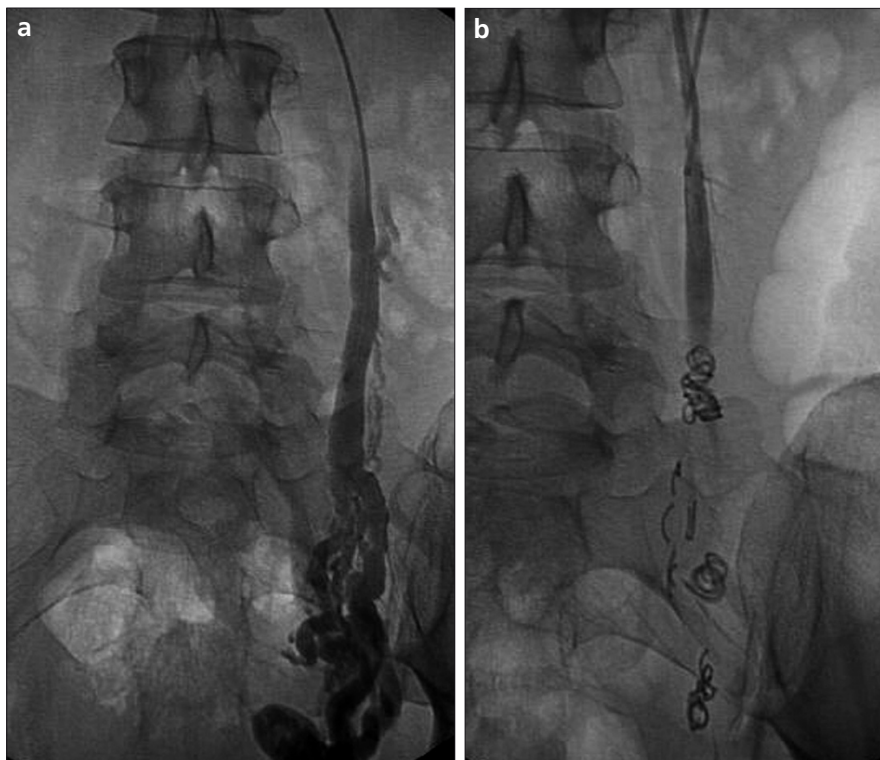
### Case 2

A 25-year-old woman was referred to our hospital with a 4-year history of infertility. She had never been pregnant. She complained of periodic mild pelvic pain and dysmenorrhea. Her symptoms were aggravated by standing for a long time, and they increased during sexual activity. No pathological changes were observed on gynecologic examination or en-

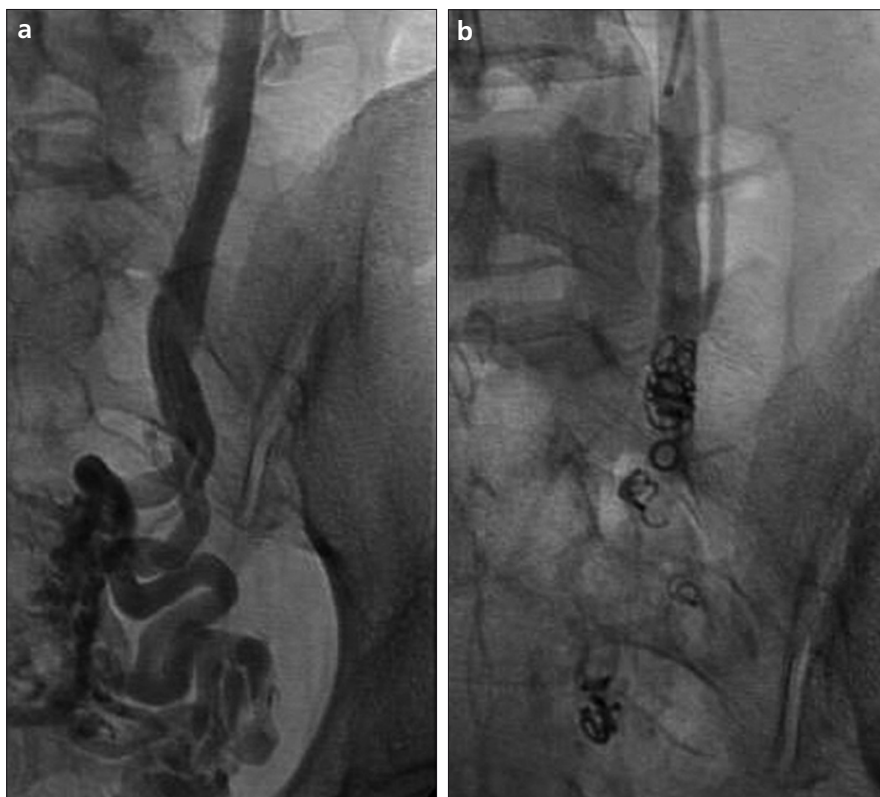From the Department of Angio/Interventional Radiology (P.T.)  
✉ tarazov@mail.ru, Russian Scientific Center of Radiology and  
Surgical Technologies, St. Petersburg, Russian Federation.

Received 9 March 2009; revision requested 2 May 2009; revision received  
21 July 2009; accepted 26 July 2009.

Published online 28 December 2009  
DOI 10.4261/1305-3825.DIR.2716-09.3



**Figure 1. a, b.** Venograms of Case 1 before (a) and after (b) embolization with steel coils. The left ovarian vein was dilated up to 12 mm with retrograde venous flow before embolization (a).



**Figure 2. a, b.** Venograms of Case 2 before (a) and after (b) embolization with steel coils. The left ovarian vein was dilated up to 11 mm and very tortuous (a). The vein was occluded after embolization (b).

dochrine evaluation. Proximal (isthmic) occlusion of uterine tubes was noted on hysterosalpingography. Abdominal ultrasound revealed left ovarian vein varicosis.

Transcervical recanalization of both fallopian tubes was successful. Nevertheless, the patient did not become pregnant within 24 months. Transcatheter embolization of the left ovarian vein was performed with 4 steel coils in a right femoral approach using a Cobra 2 catheter (Fig. 2).

After the procedure, the patient had a reduction of pelvic pain, and her dysmenorrhea resolved. In 4 months' time, an extrauterine pregnancy occurred in the left fallopian tube. The tube was resected surgically. Subsequently, the patient did not become pregnant.

### Discussion

The underlying cause of either a testicular or an ovarian varicocele is congenital insufficiency of venous valves. According to autopsy data, valves were absent in the left ovarian vein in 15% of women, and in the right ovarian vein in 6% (8). Heavy physical activity, and stenosis of the left renal vein contribute to dilatation of the ovarian veins. During pregnancy, the diameter of the ovarian veins increases several fold. According to the literature, multiple pregnancies are a major factor in the pathogenesis and progression of pelvic varicosities, which is considered to be a secondary phenomenon in multiparous women (3, 9).

Noninvasive imaging investigations such as US, computed tomography (CT), or magnetic resonance imaging (MRI) are used to confirm the clinical suspicion of pelvic varicosities. Pelvic US (transabdominal or transvaginal) is often the first-line examination (10, 11). With CT, the tubular structure of dilated ovarian veins and the pattern of their enhancement after intravenous administration of contrast medium allow the investigator to distinguish them from adnexal masses or lymphadenopathy (12, 13). MRI is the preferred noninvasive modality because it avoids radiation, and allows a complete evaluation of the pelvic anatomy due to its multiplanar capability (14). Despite these advantages, direct visualization of dilated and tortuous ovarian veins by selective venography remains the gold standard of diagnosis (2, 9).

Surgical or laparoscopic ligation of the ovarian veins is used to treat symptomatic pelvic congestion. In 1991, Galkin et al. (7) described a more technologically advanced method of transcatheter embolization, which offers the advantage of being significantly less invasive than surgical methods.

Several publications have described the successful use of embolization with both left and bilateral ovarian veins (1–6, 15, 16). Most authors prefer the femoral approach, although transjugular and brachial approaches have been described (2, 16). A common technique of ovarian varicose vein occlusion includes embolization with steel coils (1, 7, 15). This technique is simple, effective, and inexpensive. Other methods include embolization with coils and gelfoam (sandwich technique), occlusion with glue, and the use of sclerosing agents (2, 4, 16). We commonly use femoral approach and embolization with coils (5).

Galkin et al. (7) also speculated that ovarian varices can be the cause of infertility as in the case of testicular varicocele. This speculation was confirmed by their clinical study: 14 of 19 patients with patent fallopian tubes became pregnant after successful embolization of dilated ovarian veins. Unfortunately, except for the aforementioned study, no other data in the literature corroborate or challenge this observation.

Both of our patients became pregnant after successful ovarian vein embolization. In the first case, the pregnancy resulted in normal delivery.

Extrauterine pregnancy in the second case can be explained by many factors. Previous recanalization of the fallopian tubes may be one contributing factor. According to some authors, the rate of extrauterine pregnancy is 1.3–1.5 times greater after this procedure (17).

Our case reports suggest that ovarian varicocele may be associated with infertility. To prove this hypothesis, it would be necessary to conduct a retrospective analysis of a large group of women who were treated with embolization and subsequently attempted to become pregnant.

#### References

1. Edwards RD, Robertson IR, MacLean AB, Hemingway AP. Pelvic pain syndrome: successful treatment of a case by ovarian vein embolization. *Clin Radiol* 1993; 47:429–431.
2. Machan L, Martin ML. Ovarian vein embolization for pelvic congestion syndrome. *Semin Intervent Radiol* 2000; 17:277–284.
3. Scultetus AH, ViUavencio JL, Gillespie DL, Kao TC, Rich NM. The pelvic venous syndromes: analysis of our experience with 57 patients. *J Vase Surg* 2002; 36:881–888.
4. Maleux G, Stockx L, Wilms G, Marchal G. Ovarian vein embolization for the treatment of pelvic congestion syndrome: long-term technical and clinical results. *J Vase Interv Radiol* 2000; 11:859–864.
5. Tarazov PG, Prozorovskij KV, Ryzhkov VK. Pelvic pain syndrome caused by ovarian varices: treatment by transcatheter embolization. *Acta Radiologica* 1997; 38:1023–1025.
6. Venbrux AC, Chang AH, Kim HS, et al. Pelvic congestion syndrome (pelvic venous incompetence): impact of ovarian and internal iliac vein embolotherapy on menstrual cycle and chronic pelvic pain. *J Vase Interv Radiol* 2002; 13:171–178.

7. Galkin EV, Grakova LS, Naumova EB. Roentgenoendovascular surgery of ovarian hypofunction in ovarian varicocele. *Vestnik Roentgenologii* 1991; 5:51–59.
8. Ahlberg NE, Bartley O, Chidekel N. Right and left gonadal vein: an anatomical and statistical study. *Acta Radiol [Diagn]* 1966; 4:593–601.
9. Ganeshan A, Upponi S, Hon L-Q, Uthappa MC, Warakaulle DR, Uleroi R. Chronic pelvic pain due to pelvic congestion syndrome: the role of diagnostic and interventional radiology (review). *Cardiovasc Intervent Radiol* 2007; 30:1105–1111.
10. Park SJ, Lim JW, Ko YT, et al. Diagnosis of pelvic congestion syndrome using transabdominal and transvaginal sonography. *AJR Am J Roentgenol* 2004; 182:683–688.
11. Ratnam LA, Marsh P, Holdstock JM, et al. Pelvic vein embolization in the management of varicose veins. *Cardiovasc Intervent Radiol* 2008; 31:1159–1164.
12. Rozeblit AM, Ricci ZJ, Tuvia J, Amis ES. Incompetent and dilated ovarian veins: a common CT finding in asymptomatic parous women. *AJR Am J Roentgenol* 2001; 176:119–122.
13. Karaosmanoglu D, Karcaaltincaba M, Karcaaltincaba D, et al. MDCT of the ovarian vein: normal anatomy and pathology. *AJR Am J Roentgenol* 2009; 192:295–299.
14. Coakley FV, Varghese SL, Hricak H. CT and MRI of pelvic varices in women. *J Comput Assist Tomogr* 1999; 23:429–434.
15. Kwon SH, Oh JH, Ko KR, Park HC, Huh JY. Transcatheter ovarian vein embolization using coils for the treatment of pelvic congestion syndrome. *Cardiovasc Intervent Radiol* 2007; 30:655–661.
16. Gandini R, Chiochi M, Konda D, Pampana E, Fabiano S, Simonetti G. Transcatheter foam sclerotherapy of symptomatic female varicocele with sodium-tetradecyl-sulfate foam. *Cardiovasc Intervent Radiol* 2008; 31:778–784.
17. Lang EK. Transvaginal recanalization of occluded ovarian tubes. *Minim Invas Ther* 1995; 4:129–135.